


## ORIGINAL RESEARCH ARTICLE

# Progenitor-cell-enriched micrografts as a novel option for the management of androgenetic alopecia

Rafael G. Ruiz<sup>1\*</sup> | Jose M. C. Rosell<sup>1\*</sup> | Gabriele Ceccarelli<sup>2</sup> | Ciro De Sio<sup>3</sup> |  
Gabriella C. De Angelis<sup>2</sup> | Hernan Pinto<sup>4</sup> | Carlo Astarita<sup>5,6</sup>  | Antonio Graziano<sup>5,6</sup>

<sup>1</sup>GIRO-KLINIC, Girona, Spain

<sup>2</sup>Department of Public Health, Experimental Medicine and Forensics, Center for Health Technologies, University of Pavia, Pavia, Italy

<sup>3</sup>Private practice of Plastic Surgeon, Rome, Italy

<sup>4</sup>Biomedical Research Institute i2e3, Barcelona, Spain

<sup>5</sup>Department of R&D, Human Brain Wave, Turin, Italy

<sup>6</sup>Department of Biology, Sbarro Institute for Cancer Research and Molecular Medicine, College of Science and Technology, Temple University, Philadelphia, Pennsylvania

## Correspondence

Carlo Astarita, Human Brain Wave, corso Galileo Ferraris 63, 10128 Turin, Italy.  
Email: carloastarita@gmail.com

## Abstract

Regenerative medicine is a multidisciplinary field that combines engineering and life science principles to promote regeneration, potentially restoring the physiological condition in diseased tissues. Specifically, the developments of complex grafts enhance the intrinsic regenerative capacity of the host by altering its environment. Autologous micrografts obtained through Rigenera<sup>®</sup> micrografting technology are able to promote derma and bone regeneration. Androgenetic alopecia (AGA) leads to a progressive thinning of scalp hair affecting 60–70% of the adult population worldwide. Pharmacological treatment offers moderate results and hair transplantation represents the only permanent treatment option. The aim of this study was to demonstrate the role of dermis micrografting in the treatment of AGA by clinical and histological evaluations after 4, 6, and 12 months. Hair growth and density were improved at all indicated times. Those outcomes were also confirmed by the TrichoScan<sup>®</sup> analysis, reporting an increase of total hair count and density with an increase and reduction of anagen and telogen phases, respectively. Scalp dermoscopic analysis showed an improvement of hair density and histological analysis indicated a clear amelioration of the scalp, development of hair follicles, and a beginning of cuticle formation. Collectively, those results suggest a possible use of the micrografts as a novel therapeutic option in the management of AGA.

## KEYWORDS

androgenetic alopecia, micrograft, regenerative medicine

## 1 | INTRODUCTION

Androgenetic alopecia (AGA) is characterized by the presence of several nonfunctional but still-alive hair follicles, referred to as “miniaturized follicles” and their amount is directly related with the severity of the disease (Yazdabadi, Magee, Harrison, & Sinclair, 2008). Clinically, AGA is a hereditary androgen-dependent condition, characterized by a progressive thinning of scalp hair, followed by a defined pattern that affects 60–70% of the adult population worldwide up to 40% of women

and 50% of men by the age of 50 (Varothai & Bergfeld, 2014). The pharmacological treatment of AGA constitutes a multibillion-dollar industry frequently offering only moderate results. Such treatments also require the chronic application to achieve the continued benefit, with the risk of developing adverse side effects (Santos, Avci, & Hamblin, 2015) and strongly decreasing patient compliance. For this reason, hair transplantation represents the only current successful permanent treatment option, even if it requires a fairly invasive surgical procedure (Jain & De-Eknamkul, 2014; Levy & Emer, 2013). Actually, hair transplantation can be performed by two principal techniques, follicular unit transplant and follicular unit extraction, both are widely described in the literature (Jiménez-Acosta & Ponce-Rodríguez, 2017; Saxena

\*Rafael G. Ruiz and Jose M. C. Rosell contributed equally to this study.

& Savant, 2017). Another approach widely used is the injection of autologous platelet-rich plasma (PRP), which is able to reduce swelling and pain while increasing hair density (Ferneck, Beauvais, Castiglione, & Ferneck, 2017; Li et al., 2012).

The Rigenera<sup>®</sup> technology is an innovative clinical approach to obtain in one surgical time autologous micrografts able to promote derma and bone regeneration. This technology allows the mechanical disaggregation of small tissue samples previously harvested from the patient. Lastly, the device performs also a selective filtration, collecting only the cells and tissue particles smaller than 80  $\mu\text{m}$ . At the end of the procedure, which lasts only 2 min, the micrografts are collected from the reservoir located at the bottom of the Rigenera device. The regenerative role of micrografts was also reported in several *in vitro* studies, and more important, displayed high positivity to mesenchymal stem cells markers such as CD73, CD90, and CD105. Therefore, the obtained autologous micrografts were identified as progenitor-cell-enriched micrografts (Monti et al., 2017; Trovato et al., 2015). In the past, a preliminary study on three patients that underwent hair transplantation reported that the autologous micrografts obtained by Rigenera<sup>®</sup> were able to promote continuous hair growth even 2 months after the procedure with a shortening of the dormant phase of the follicle and faster healing of the microwounds. The authors postulate that the micrograft induced a strong and selective regenerative effect on the scalp of the patients (Zanzottera, Lavezzari, Trovato, Icardi, & Graziano, 2014). Based on these evidence, the aim of this study was to demonstrate the efficacy and safety of the progenitor-cell-enriched micrograft in the management of AGA. The clinical evaluations were performed after 4, 6, and 12 months from the micrografts application. Lastly, we have also performed histological and dermoscopic evaluation after 6 and 9

months from treatment highlighting the biological effect of the micrografts in a patient affected by AGA.

## 2 | SUBJECTS AND METHODS

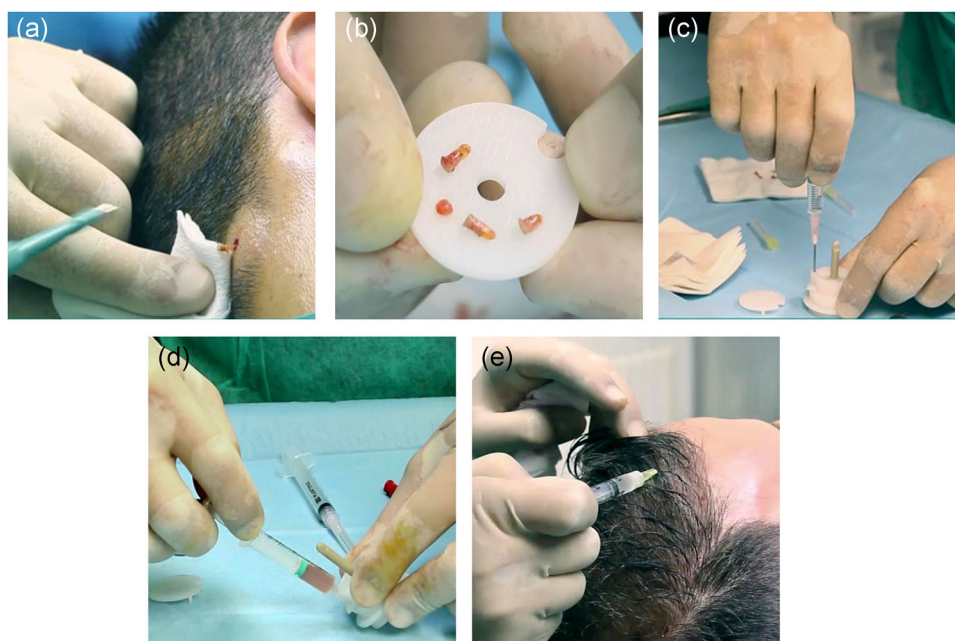
### 2.1 | Subjects

AGA diagnoses were established based on a detailed medical history (i.e., screening for drugs linked to hair loss), clinical examination, and trichoscopic features (i.e., >20% variability in hair diameter between affected and unaffected areas). Subjects were clinically diagnosed with AGA upon presentation of an increase in miniaturized terminal hair and/or a reduced number of hair after physical examination and phototrichograms, along with negative hair pull tests. A total of 100 patients were treated according to the criteria defined before. Exclusion criteria were allergy to lidocaine, healing issues, chronic drug treatment, oncologic processes, and the execution of hair loss treatment between 3 months prior and 3 months after the date of applying treatment (except taking vitamin supplements and applying topical lotions or shampoos).

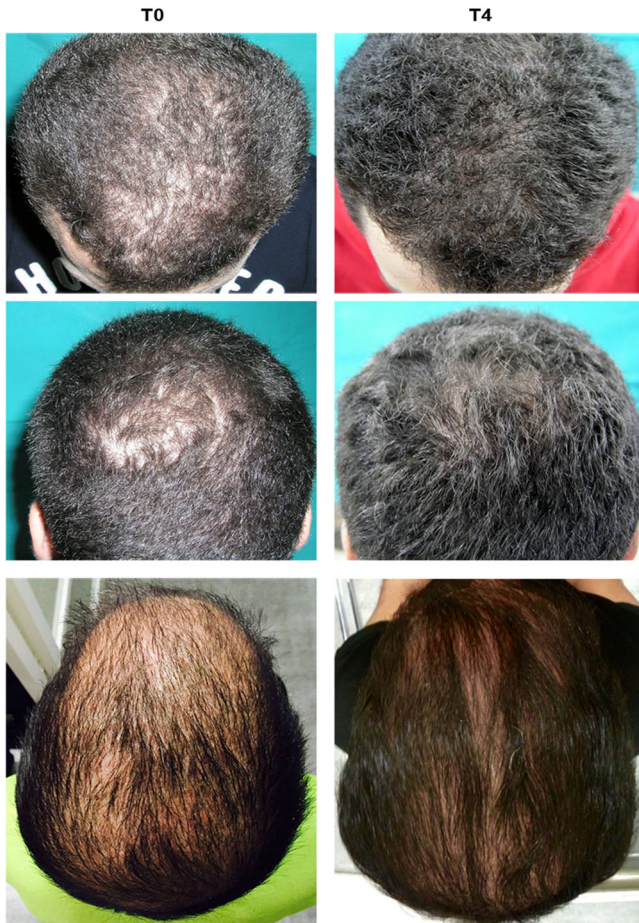This study protocol is in accordance with the Declaration of Helsinki and the European regulations. All the patients provided written informed consent before participating in the study.

### 2.2 | Micrografts collection

The micrografts were prepared using the innovative medical device Rigeneracons (CE certified class I; Human Brain Wave, Turin, Italy). A 3 mm punch biopsy was used to extract 3 scalp tissues samples (Figure 1a) disaggregated by Rigeneracons adding 1.5 ml of sterile physiologic solution to the device (Figure 1b,c). The rotation of



**FIGURE 1** Procedure to collect autologous micrografts. (a), Punch biopsy to extract scalp tissue. (b, c) The strips of scalp tissue are placed into the Rigeneracons medical device adding 1.5 ml of sterile physiologic solution. (d) Collection of micrografts suspension by syringe without needle. (e) Infiltration of micrografts into the scalp of the patients



**FIGURE 2** Three different representative cases of male patients before and after 4 months from micrografts application

Rigeneracons at 80 RPM by using the Rigenera machine for 2 min allows us to obtain the micrografts that were collected (Figure 1d) and directly infiltrated into the scalp of the patients as a mesotherapy (Figure 1e).

### 2.3 | TrichoScan<sup>®</sup> test

TrichoScan<sup>®</sup> (Teachscreen Software; Fotofinder, Bad Birnbach, Germany) is a computer-assisted dermoscopy with dedicated software to diagnose the hair loss and to measure its severity. Miniaturization is a pivotal requisite for establishing the AGA diagnosis. We randomly performed this test on 10 patients, as previously described (Riedel-Baima & Riedel, 2009). Briefly, an area of approximately 1 cm<sup>2</sup> on the parietal scalp was clipped with approximately 1 mm length. After 48 hr, a hair dye over that area was applied rinsing it 20 min later with a diluted alcoholic solution. Afterward, a microscopic image at  $\times 20$  was taken and analysis with TrichoScan<sup>®</sup> of the area was performed.

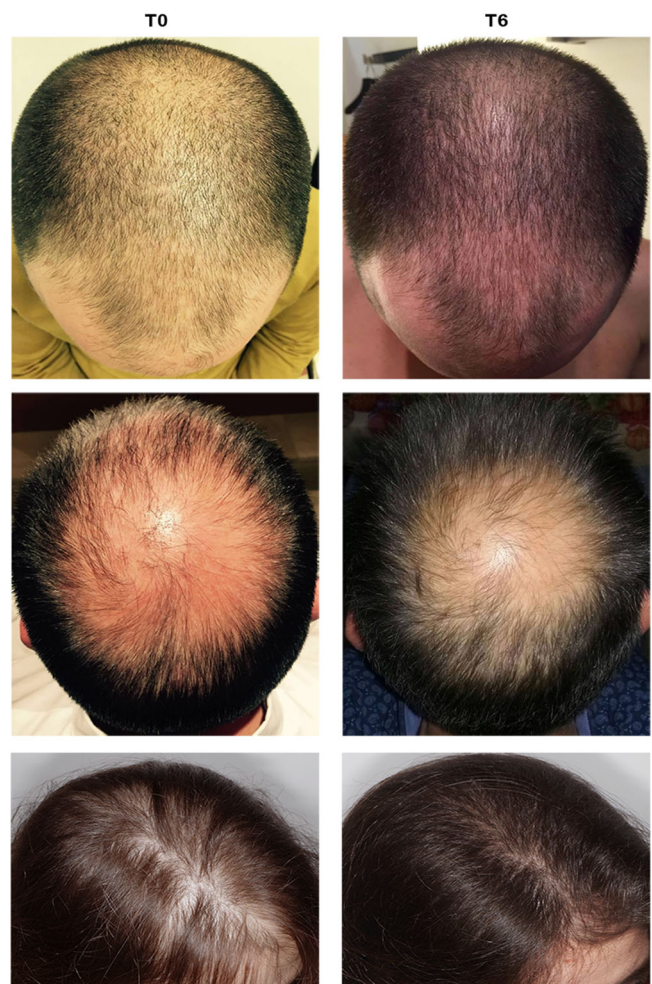
### 2.4 | Clinical evaluations

All the patients were evaluated at time 0 before the treatment, and after 4, 6, or 12 months from treatment and the effects of autologous

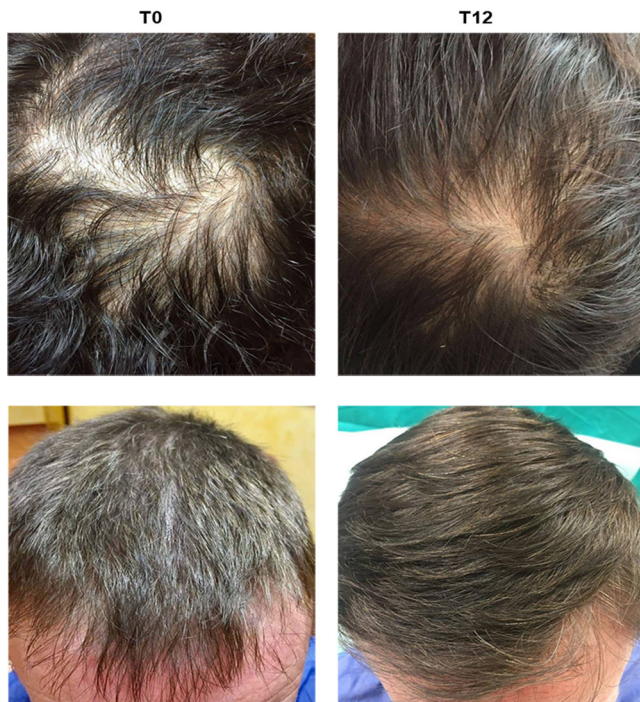
micrografts on hair growth were assessed with the help of global photography, physician's and patient's global assessment scale.

### 2.5 | Histological evaluation of biopsies

Scalp biopsies were collected before and after 6 or 9 months from micrografts treatment, using a 4-mm punch probe from volunteer subjects. The biopsies were taken from the occipital region of the scalp, immediately fixed in 10% formalin and embedded in paraffin block to be cut and mounted onto microscope slides for analysis (Hashimoto et al., 2000). Biopsies were sectioned with ordinary microtome into 5- $\mu$ m sections both vertically (parallel to the long axis of hair follicle) and transversely (perpendicular to the long axis of follicle and parallel to epidermis down toward subcutis). Histological sections were mounted on a glass slide sequentially and stained by Mallory's trichrome staining, as previously described, to visualize the collagen of connective tissue (highlighted by a blue coloration; Heidari et al., 2016). In addition, follicles were characterized as anagen, catagen, and telogen.



**FIGURE 3** Three different representative cases of two male and one female patients before and after 6 months from micrografts application



**FIGURE 4** Two different representative cases of two male patients before and after 12 months from micrografts application

### 3 | RESULTS

The clinical evaluations of the use of the micrografts in the treatment of AGA were performed after 4, 6, and 12 months from micrografts application reporting significant improvement of hair growth and density at all indicated times (Figures 2–4). The visual results are confirmed by TrichoScan<sup>®</sup> analysis as reported in Table 1 (representative for a large number of patients) where it can be observed an increase of total hair count and hair density accomplished by an increase and reduction of anagen and telogen phases, respectively, after the micrografts application. The mean increase in total hair density was of  $30\% \pm 3.0\%$  already after 2 months of treatment compared with baseline values for the treated area. In addition, scalp dermoscopic analysis also showed an improvement of hair density after both 4 and 6 months from treatment (Figure 5).

Histological evaluations were performed by Mallory's trichrome staining on scalp biopsies at baseline and after 6 and 9 months from micrografts application. Figure 6 is representative of a large number of scalp biopsies. In the upper panels at baseline, the morphological appearance of the scalp is characterized by few hair follicles, lymphocytes infiltration, and prevalence of adipose tissue (Figure 6a,b). After 6 months of micrografts application, the number of hair follicles is higher with the beginning of cuticle formation and dermal papilla in proliferation (Figure 6c,d). In this case, it is possible to visualize a significant improvement in the anagen III phase with respect to baseline. In the lower panels, we reported the results after 9 months from the micrografts application. At baseline, we can observe an irregular derma, characterized by thin thickness, thin dermal papilla, indicating a lacking cellular proliferation. In addition, few hair follicles in the anagen III phase

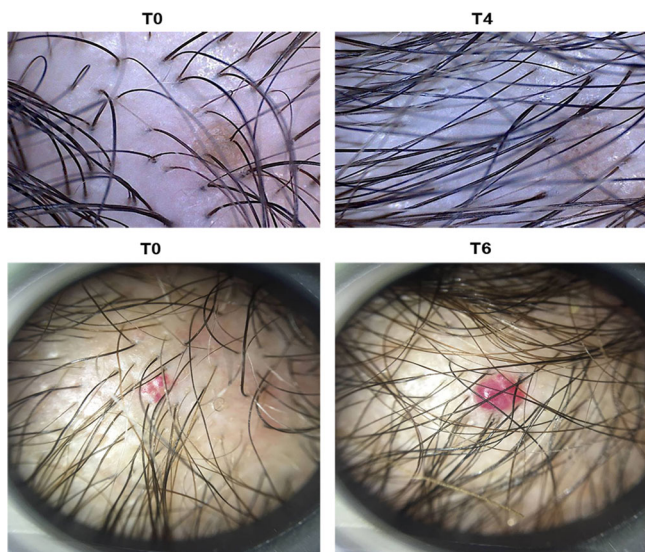
**TABLE 1** Representative evaluation of hair growth by TrichoScan<sup>®</sup> assay (A) before and (B) after 2 months of treatment

A	
Trichogram	
Area (cm <sup>2</sup> )	0.72
Total hair count	11.0
Hair density (1/cm <sup>2</sup> )	15.2
Anagen hairs (%)	72.7
Telogen hairs (%)	27.3
Hair length median (mm)	0.69
Density vellus hairs (1/cm <sup>2</sup> )	2.1
Density terminal hairs (1/cm <sup>2</sup> )	13.2
Count vellus	1.5
Count terminal	9.5
Ratio vellus hairs (%)	13.6
Ratio terminal hairs (%)	86.4
B	
Trichogram	
Area (cm <sup>2</sup> )	0.72
Total hair count	35.0
Hair density (1/cm <sup>2</sup> )	48.5
Anagen hairs (%)	78.3
Telogen hairs (%)	21.7
Hair length median (mm)	0.65
Density vellus hairs (1/cm <sup>2</sup> )	10.4
Density terminal hairs (1/cm <sup>2</sup> )	38.1
Count vellus	7.5
Count terminal	27.5
Ratio vellus hairs (%)	21.4
Ratio terminal hairs (%)	78.6

were observed (Figure 6e,f). After 9 months, we reported a well-organized derma, more regular, structured collagen fiber, and hair follicles in Anagen IV/Mesagen phase. We also observed thick dermal papilla and signs of cellular proliferation (Figure 6g,h).

### 4 | DISCUSSION

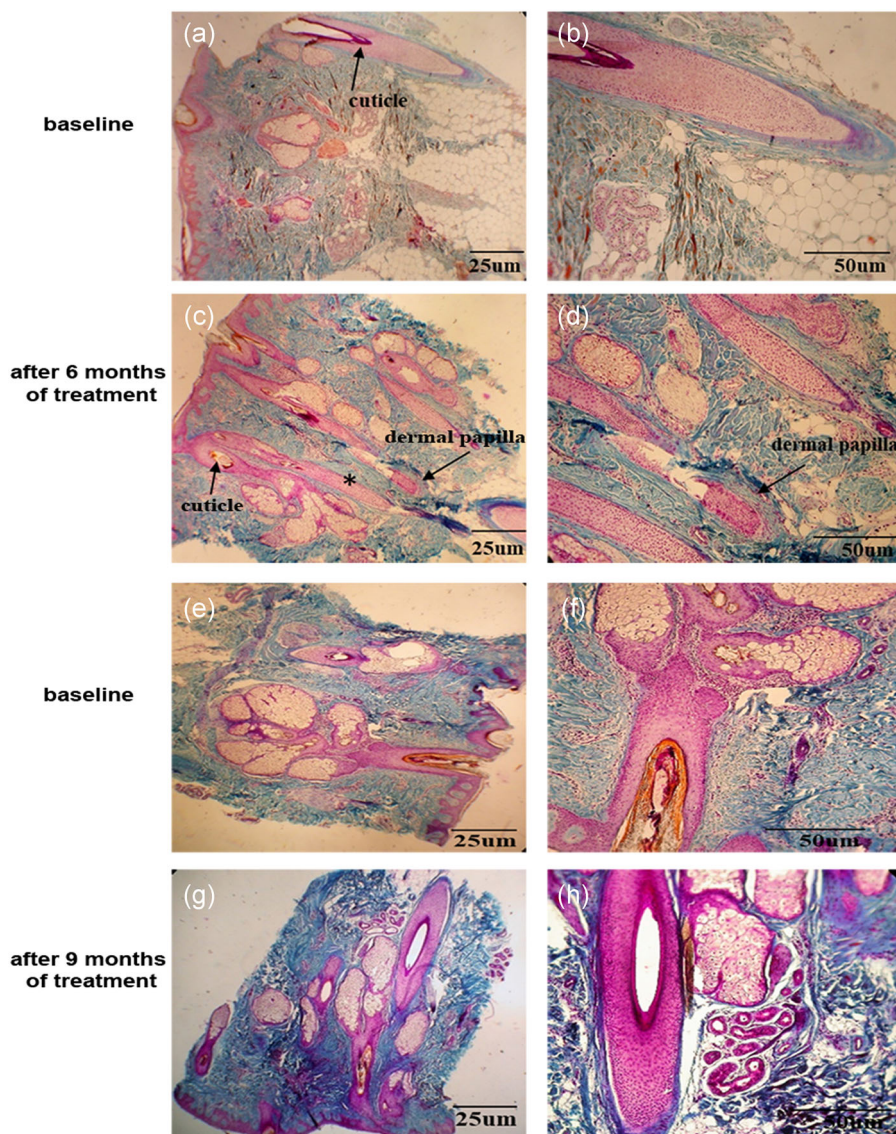
The hair growth cycle is composed of three stages, anagen, catagen, and telogen. The AGA is a pathological condition characterized by an unbalance between the anagen and telogen phases with a reduction and increase of these phases, respectively. For this reason, a therapeutic approach able to stimulate hair follicles growth is commonly suggested. Many hair growths promoting therapies, such as minoxidil, PRP, and topical steroids were already identified (Chueh et al., 2013). Currently, minoxidil and finasteride are the only Food and Drug Administration (FDA) approved drugs; low-level laser light therapy is the only FDA-cleared device for the treatment of AGA and a



**FIGURE 5** Scalp dermoscopic analysis performed by TrichoScan® before and after 4 and 6 months from micrografts application

recent published meta-analysis confirms the efficacy of these treatments with respect to placebo (Adil & Godwin, 2017). In addition to pharmacological treatment, there is a growing interest in alternative treatment strategy such as the use of growth factors or stem cells (Giordano, Romeo, & Lankinen, 2017; Park et al., 2010; Yoo et al., 2010). However, the use of stem cells is complex from the regulatory prospective and often not permitted. The use of the Rigenra devices allowed physicians and researchers to disaggregate the patient's own tissue, collecting progenitor-cell-enriched micrograft. Progenitors are a population of cells, resident in many tissues in the body, addressed to the regeneration, when possible, of the same tissue after injuries. Such cells express some of the stem cells' markers; however, differently from stem cells, progenitor cells are often unipotent and with limited capabilities of self-renewal (Seaberg & van der Kooy, 2003).

In this study, we have reported the effect of autologous micrografts on hair follicles restoration showing an improvement of hair growth and density after treatment, as demonstrated by photographs and TrichoScan® analysis. In accordance to these



**FIGURE 6** (a, b, e, and f) Histological evaluation of the occipital region of the scalp at baseline and after (c and d) 6 (g and h) and 9 months from micrografts application. The biopsies sections were stained by Mallory's trichrome. The symbol \* indicates the presence of lymphocytes infiltration in the hair follicle. Magnification  $\times 4$ , scale bar = 25  $\mu\text{m}$ ; magnification  $\times 20$ , scale bar = 50  $\mu\text{m}$

data, a recent published study showed an increase of hair density after 6 months from treatment with human follicular cells isolated by the Rigenera® device without the need of culture conditions (Gentile, Scioli, Bielli, Orlandi, & Cervelli, 2017). In the same study, the authors also reported a good percentage of hair follicle CD44+cells, from the dermal papilla, and hair follicle epithelial CD200+cell, from the bulge suggesting their role in the hair follicle growth.

To confirm the effectiveness of autologous micrografts, other recent studies reported an increase of hair thickness together with a reduction of hair loss and a good patient's level of satisfaction after micrografts application. Furthermore, the treatment was well tolerated concerning pain without side effects (Álvarez, Valenzuela, & Tuffet, 2017; Álvarez, Valenzuela, & Tuffet, 2018).

In addition, the regenerative potential of the micrografts and the clinical efficacy have been already shown for bone regeneration (Brunelli et al., 2013; Rodriguez et al., 2017), in the treatment of ulcers (De Francesco et al., 2017; Miranda, Farina, & Farina, 2018; Trovato, Failla, Serantoni, & Palumbo, 2016), wound dehiscences (Baglioni, Trovato, Marcarelli, Frenello, & Bocchiotti, 2016; Marcarelli, Trovato, Novarese, Riccio, & Graziano, 2017), pathological scars (Svolacchia, De Francesco, Trovato, Graziano, & Ferraro, 2016), and lastly for cartilage and cardiac regeneration (Ceccarelli et al., 2017; Lampinen, Nummi, Nieminen, Harjula, & Kankuri, 2017; Gentile, Scioli, Bielli, Orlandi, & Cervelli, 2016).

Histological analysis performed in this study is suggestive for the role of micrografts in the development of new hair follicles (beginning of cuticle formation, increase of hair follicles, and decrease in adipose tissue). Based on the regenerative properties of micrografts, we can suppose two probable mechanisms for this effect. The first is the ability of micrografts to stimulate the quiescent hair follicular units reverting the miniaturization process typical of AGA and the second is the ability to induce the development of new hair follicles. Nevertheless, further and focused in vitro studies are needed to assess and confirm these suggestions. After the micrografts application, it was reported an improvement in hair restoration accomplished by a positive patient's subjective assessment. Taken together, these results are promising for major use of micrografts in the treatment of AGA, even if controlled and randomized clinical trials, with a larger sample, control, and placebo groups are necessary to confirm these effects.

## CONFLICT OF INTERESTS

The authors Carlo Astarita and Antonio Graziano are members of Scientific Division of Human Brain Wave, the company owner of Rigenera TM technology. The other authors declare no competing interests.

## ORCID

Carlo Astarita  <http://orcid.org/0000-0003-3010-9878>

## REFERENCES

- Álvarez, X., Valenzuela, M., & Tuffet, J. (2018). Clinical and histological evaluation of the Regenera® method for the treatment of androgenetic alopecia. *International Educational Applied Scientific Research Journal*, 3(1), 2456–5040.
- Álvarez, X., Valenzuela, M., & Tuffet, J. (2017). Microscopic and histologic evaluation of the Regenera® method for the treatment of androgenetic alopecia in a small number of cases. *International Journal of Research Studies in Medical and Health Sciences*, 2(8), 19–22.
- Adil, A., & Godwin, M. (2017). The effectiveness of treatments for androgenetic alopecia: A systematic review and meta-analysis. *Journal of the American Academy of Dermatology*, 77(1), 136–141.e5.
- Baglioni, E., Trovato, L., Marcarelli, M., Frenello, A., & Bocchiotti, M. A. (2016). Treatment of oncological post-surgical wound dehiscence with autologous skin micrografts. *Anticancer Research*, 36(3), 975–979.
- Brunelli, G., Motroni, A., Graziano, A., D'Aquino, R., Zollino, I., & Carinci, F. (2013). Sinus lift tissue engineering using autologous pulp micrografts: A case report of bone density evaluation. *Journal of Indian Society of Periodontology*, 17(5), 644–647. <https://doi.org/10.4103/0972-124X.119284>
- Ceccarelli, G., Gentile, P., Marcarelli, M., Balli, M., Ronzoni, F. L., Benedetti, L., & De Angelis MG, C. (2017). In vitro and in vivo studies of alar-nasal cartilage using autologous micro-grafts: The use of the Rigenera® protocol in the treatment of an osteochondral lesion of the nose. *Pharmaceuticals*, 10(2), 53. <https://doi.org/10.3390/ph10020053>
- Chueh, S. C., Lin, S. J., Chen, C. C., Lei, M., Wang, L. M., Wideltz, R., ... Chuong, C. M. (2013). Therapeutic strategy for hair regeneration: Hair cycle activation, niche environment modulation, wound-induced follicle neogenesis, and stem cell engineering. *Expert Opinion on Biological Therapy*, 13, 377–391.
- De Francesco, F., Graziano, A., Trovato, L., Ceccarelli, G., Romano, M., Marcarelli, M., ... Ferraro, G. A. (2017). Erratum to: A regenerative approach with dermal micrografts in the treatment of chronic ulcers. *Stem Cell Reviews and Reports*, 13(1), 149. <https://doi.org/10.1007/s12015-016-9698-9>
- Ferneini, E. M., Beauvais, D., Castiglione, C., & Ferneini, M. V. (2017). Platelet-rich plasma in androgenic alopecia: Indications, technique, and potential benefits. *Journal of Oral and Maxillofacial Surgery*, 75(4), 788–795. <https://doi.org/10.1016/j.joms.2016.10.040>
- Gentile, P., Scioli, M. G., Bielli, A., Orlandi, A., & Cervelli, V. (2016). A combined use of chondrocytes micro grafts (CMG) mixed with platelet rich plasma (PRP) in patients affected by pinch nose deformity. *Journal of Regenerative Medicine*, 5(2), <https://doi.org/10.4172/2325-9620.1000129>
- Gentile, P., Scioli, M. G., Bielli, A., Orlandi, A., & Cervelli, V. (2017). Stem cells from human hair follicles: First mechanical isolation for immediate autologous clinical use in androgenetic alopecia and hair loss. *Stem Cell Investigation*, 4, 58. <https://doi.org/10.21037/sci.2017.06.04>
- Giordano, S., Romeo, M., & Lankinen, P. (2017). Platelet-rich plasma for androgenetic alopecia: Does it work? Evidence from meta-analysis. *Journal of Cosmetic Dermatology*, 16(3), 374–381.
- Hashimoto, T., Kazama, T., Ito, M., Urano, K., Katakai, Y., Yamaguchi, N., & Ueyama, K. (2000). Histologic and cell kinetic studies of hair loss and subsequent recovery process of human scalp hair follicles grafted onto severe combined immunodeficient mice. *Journal of Investigative Dermatology*, 115(2), 200–206.
- Heidari, F., Yari, A., Rasoolijazi, H., Soleimani, M., Dehpoor, A., Sajedi, N., ... Nobakht, M. (2016). Bulge hair follicle stem cells accelerate cutaneous wound healing in rats. *Wounds*, 28(4), 132–141.
- Jain, R., & De-Eknamkul, W. (2014). Potential targets in the discovery of new hair growth promoters for androgenic alopecia. *Expert Opinion on Therapeutic Targets*, 18, 787–806.

- Jiménez-Acosta, F., & Ponce-Rodríguez, I. (2017). Actualización del método Follicular Unit Extraction (FUE) del trasplante de pelo. *Actas Dermo-Sifiliográficas*, 108, 532–537.
- Lampinen, M., Nummi, A., Nieminen, T., Harjula, A., & Kankuri, E. (2017). Intraoperative processing and epicardial transplantation of autologous atrial tissue for cardiac repair. *The Journal of Heart and Lung Transplantation*, 36(9), 1020–1022. <https://doi.org/10.1016/j.healun.2017.06.002>
- Levy, L. L., & Emer, J. (2013). Female pattern alopecia: Current perspectives. *International Journal of Women's Health*, 5, 541–556.
- Li, Z. J., Choi, H. I., Choi, D. K., Sohn, K. C., Im, M., Seo, Y. J., ... Lee, Y. (2012). Autologous platelet-rich plasma: A potential therapeutic tool for promoting hair growth. *Dermatologic Surgery*, 38(7 Pt 1), 1040–1046. <https://doi.org/10.1111/j.1524-4725.2012.02394.x>
- Marcarelli, M., Trovato, L., Novarese, E., Riccio, M., & Graziano, A. (2017). Rigenera protocol in the treatment of surgical wound dehiscence. *International Wound Journal*, 14(1), 277–281. <https://doi.org/10.1111/iwj.12601>
- Miranda, R., Farina, E., & Farina, M. A. (2018). Micrografting chronic lower extremity ulcers with mechanically disaggregated skin using a micrograft preparation system. *Journal of Wound Care*, 27(2), 60–65.
- Monti, M., Graziano, A., Rizzo, S., Perotti, C., Del Fante, C., d'Aquino, R., ... Rodríguez y Baena, R. (2017). In vitro and in vivo differentiation of progenitor stem cells obtained after mechanical digestion of human dental pulp. *Journal of Cellular Physiology*, 232, 548–555.
- Park, B. S., Kim, W. S., Choi, J. S., Kim, H. K., Won, J. H., Ohkubo, F., & Fukuoka, H. (2010). Hair growth stimulated by conditioned medium of adipose-derived stem cells is enhanced by hypoxia: Evidence of increased growth factor secretion. *Biomedical Research*, 31, 27–34.
- Riedel-Baima, B., & Riedel, A. (2009). Use of the TrichoScan to assess female pattern hair loss. *Dermatologic Surgery*, 35, 651–655.
- Rodríguez y Baena, R., D'Aquino, R., Graziano, A., Trovato, L., Aloise, A. C., Ceccarelli, G., ... Lupi, S. M. (2017). Autologous periosteum-derived micrografts and PLGA/HA enhance the bone formation in sinus lift augmentation. *Frontiers in Cell and Developmental Biology*, 5, 87. <https://doi.org/10.3389/fcell.2017.00087>
- Santos, Z., Avci, P., & Hamblin, M. R. (2015). Drug discovery for alopecia: Gone today, hair tomorrow. *Expert Opinion on Drug Discovery*, 10, 269–292.
- Saxena, K., & Savant, S. (2017). Body to scalp: Evolving trends in body hair transplantation. *Indian Dermatology Online Journal*, 8, 167–175.
- Seaberg, R. M., & van der Kooy, D. (2003). Stem and progenitor cells: The premature desertion of rigorous definition. *Trends in Neurosciences*, 26(3), 125–131.
- Svolacchia, F., De Francesco, F., Trovato, L., Graziano, A., & Ferraro, G. A. (2016). An innovative regenerative treatment of scars with dermal micrografts. *Journal of Cosmetic Dermatology*, 15(3), 245–253. <https://doi.org/10.1111/jocd.12212>
- Trovato, L., Failla, G., Serantoni, S., & Palumbo, F. P. (2016). Regenerative surgery in the management of the leg ulcers. *Journal of Cell Science & Therapy*, 07, 238. <https://doi.org/10.4172/2157-7013.1000238>
- Trovato, L., Monti, M., Del Fante, C., Cervio, M., Lampinen, M., Ambrosio, L., ... Graziano, A. (2015). A new medical device rigeneracons allows to obtain viable micro-grafts from mechanical disaggregation of human tissues. *Journal of Cellular Physiology*, 230, 2299–2303.
- Varothai, S., & Bergfeld, W. F. (2014). Androgenetic alopecia: An evidence-based treatment update. *American Journal of Clinical Dermatology*, 15, 217–230.
- Yazdabadi, A., Magee, J., Harrison, S., & Sinclair, R. (2008). The Ludwig pattern of androgenetic alopecia is due to a hierarchy of androgen sensitivity within follicular units that leads to selective miniaturization and a reduction in the number of terminal hairs per follicular unit. *British Journal of Dermatology*, 159, 1300–1302.
- Yoo, B. Y., Shin, Y. H., Yoon, H. H., Seo, Y. K., Song, K. Y., & Park, J. K. (2010). Application of mesenchymal stem cells derived from bone marrow and umbilical cord in human hair multiplication. *Journal of Dermatological Science*, 60, 74–83.
- Zanzottera, F., Lavezzari, E., Trovato, L., Icardi, A., & Graziano, A. (2014). Adipose derived stem cells and growth factors applied on hair transplantation. Follow-up of clinical outcome. *Journal of Cosmetics, Dermatological Sciences and Applications*, 4, 268–274. <https://doi.org/10.4236/jcdsa.2014.44036>

**How to cite this article:** Ruiz RG, Rosell JMC, Ceccarelli G, et al. Progenitor-cell-enriched micrografts as a novel option for the management of androgenetic alopecia. *J Cell Physiol*. 2019;1–7. <https://doi.org/10.1002/jcp.29335>