

## ORIGINAL ARTICLE

# Intra-articular administration of purified autologous adipose tissue for knee osteoarthritis treatment

Gianluca CASTELLARIN <sup>1,2</sup> \*, Salvatore MOSCA <sup>2</sup>, Giovanni MICERA <sup>2</sup>, Antonio MORONI <sup>2</sup>

<sup>1</sup>Department of Orthopedic Surgery 2, Suzzarra Hospital, Suzzara, Mantua, Italy; <sup>2</sup>IRCCS Galeazzi San Siro Orthopedic Clinic, San Raffaele Vita e Salute University, Milan, Italy

\*Corresponding author: Gianluca Castellarin, Department of Orthopedic Surgery 2, Suzzara Hospital, Via G. Cantore 14, 46029, Suzzara, Mantua, Italy. E-mail: [gianlucacastellarin@gmail.com](mailto:gianlucacastellarin@gmail.com)

## ABSTRACT

**BACKGROUND:** Knee osteoarthritis at its early stages can be treated using several not invasive methods. The aim of this paper is to assess the efficacy of intra-articular administration of purified adipose tissue for the treatment of knee osteoarthritis.

**METHODS:** Ninety-two patients with MRI evidence of II-III grade knee osteoarthritis (Outerbridge classification) were recruited for the study. Patients underwent a small liposuction (40-60 mL) and harvested fat was processed intraoperatively to obtain purified adipose tissue. The obtained product was injected into the symptomatic joint. Patients were interviewed for clinical evaluation with VAS and WOMAC questionnaires before treatment and at 1, 3, 6, and 12 months of follow-up. Postoperative MRI was done on a selected group of patients.

**RESULTS:** The treated patients group showed significant pain relief and functional recovery 1 month after the therapy with benefits until the last follow-up (12 months). Functional recovery measured with WOMAC Score — ameliorated from 61.5 points before the treatment to 79.5 after one month and 84 after one year. Pain — measured with VAS — significantly decreased from 5.7 to 3.1 points after one month and 1.7 after one year. MRI images showed an evident reduction or even disappearance of peri-lesional subchondral edema.

**CONCLUSIONS:** Intra-articular administration of purified adipose tissue is significantly effective in ameliorating knee osteoarthritis symptoms with effects lasting at least 1 year.

(Cite this article as: Castellarin G, Mosca S, Micera G, Moroni A. Intra-articular administration of purified autologous adipose tissue for knee osteoarthritis treatment. *Minerva Ortop Traumatol* 2020;71:93-7. DOI: 10.23736/S0394-3410.20.03976-4)

**KEY WORDS :** Osteoarthritis; Knee; Cartilage; Regenerative medicine; Adipose tissue.

**K**nee osteoarthritis (OA) is a multi-factorial disease associated with cartilage degeneration causing pain and permanent disabling symptoms.<sup>1</sup> Many pharmacological and surgical options are available to treat the patients to relieve the symptoms, but the definitive solution to provide pain relief is joint replacement. Although results are satisfying, joint replacement is an invasive treatment indicated only for the last stage of OA. Knee arthroscopy in younger patients with mild OA is not sufficient.<sup>2</sup> To overcome the limits and the risks of invasive surgeries to treat primary OA in young patients, a wide range of non-

invasive options are available. Pharmacological administration of not-steroid anti-inflammatory drugs can provide short-term patient-related benefits,<sup>3</sup> while the use of corticosteroids can worsen the clinical picture.<sup>4</sup> Intra-articular infiltration of hyaluronic acid is a non-invasive and repeatable option treatment that can provide good clinical results. Still, it has generated a lot of controversy because of the variability of products and treatment protocols, which reflects non-homogeneous results in the literature.<sup>5</sup>

Recently, interest in regenerative medicine has emerged to address cartilage regeneration

milestone. The first methods attempted to collect mesenchymal stem cells (MSCs) from different tissue sources following cell culture expansion for sequential intra-articular injection or 3D scaffolds-enrichment.<sup>6</sup> The intent was to exploit the ability of MSCs to differentiate into chondrocytes and promote cartilage regeneration.<sup>7</sup> However, researchers recently understood that MSCs are an excellent clinical tool also for the ability to release growth factors and anti-inflammatory cytokines. The paracrine effect is likely the primary mechanism of action for *in-vivo* clinical results, rather than MSCs differentiation into tissue-specific cells.<sup>8</sup> Moreover, European and American regulatory impose specific limits on cell cultures and cell modifications. Bone marrow and adipose tissue have become the main sources of MSCs because of their advantage of non-invasive harvesting and intra-operative minimal manipulation through sterile medical devices. Adipose tissue has become a trend in the past few years as a source of MSCs because of its advantage of being more abundant in MSCs frequency.<sup>9</sup> Many studies demonstrated that intra-articular administration of adipose tissue derivatives is a safe, feasible, and effective approach for OA treatment.<sup>10-12</sup> This paper aims to confirm these results in a large population of OA patients, using Lipocell, a IIa medical device that purify lipoaspirate in compliance with minimal manipulation requirements.<sup>13</sup>

## Materials and methods

### Patients recruitment

From 2017 to 2018, 92 patients with symptomatic knee OA were recruited and underwent intra-articular injection of purified adipose tissue. Selection criterium was MRI evidence of II-III grade arthrosis (Outerbridge classification). Exclusion criteria were age over 65 years,  $18 \leq$  Body Mass Index (BMI)  $\geq 30$  kg/m<sup>2</sup>, axial deformity, ligament instability, algodystrophy, synovitis, rheumatoid arthritis, kissing lesions. A group of patients underwent knee arthroscopy for LCA reconstruction, meniscectomy, patellar realignment, or knee osteotomy for varus or valgus deformity alignment – and study treatment was performed 40 days later. All patient

TABLE I.—Patients demographic data (N.=92).

Characteristics	Value
Age (year)	52 (range 18-65)
Gender	
Male	59
Female	33
Outerbridge	
II	49
III	43
Knee	
Right	54
Left	38

signed informed consent and filed WOMAC and VAS questionnaires before treatment. A summary of patients demographics can be seen on Table I.

### Sample collection and processing

Patients underwent a small liposuction (40-60 mL) after Klein infiltration (lidocaine 2% and adrenaline 1 mg/mL in 500 mL NaCl 0.9% solution). Klein infiltration and liposuction were performed with fenestrated blunt cannulae (Figure 1). 60-120 mL of lipoaspirated fat was collected from abdominal subcutaneous fat. The lipoaspirates were processed with Lipocell (Tiss'You, RSM).<sup>13</sup> According to instructions, the lipoaspirate is inserted into the device where it is dialyzed with a filter and washed with 300-500 mL of NaCl 0.9%. After 3-5 minutes the lipoaspirate appears cleans from blood and the washing solution is transparent also in the outflow tube (Figure 2); the purified lipoaspirate can be recovered with a 10 mL syringe from the output connection.

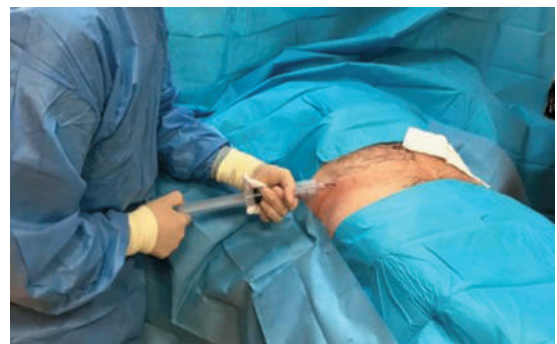

Figure 1.—Liposuction performed with a fenestrated blunt cannulae.

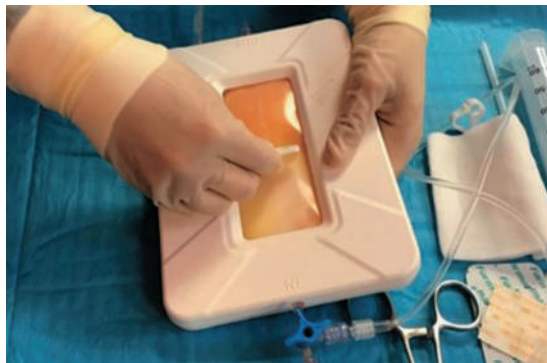

Figure 2.—Lipo-aspirate treatment.

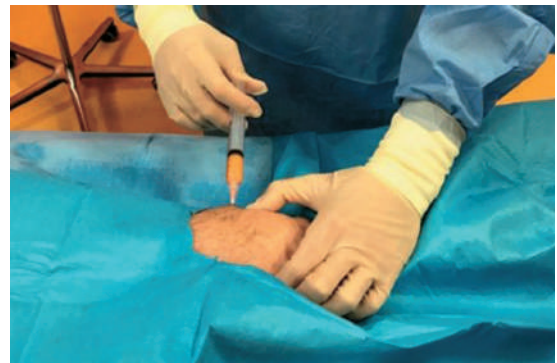

Figure 3.—The purified adipose tissue is injected in the knee joint.

### Treatment and follow-up protocol

Six mL of purified adipose tissue was injected in the knee with an 18G needle (Figure 3). Flexion-extension movement was executed after the infiltration to diffuse the product into a joint. Treated knees were partially unloaded in the first three days with the help of crutches. For every patient, quadriceps strengthening and inductive magnetic field therapy were suggested to ameliorate pain relief and functional recovery. Return to sports activity was postponed 30 days after the treatment.

### Clinical evaluation

Patients were examined for WOMAC and VAS questionnaire at 1, 3, 6, and 12 months after the treatment. A selected group of 10 patients was evaluated with MRI to observe the evolution of the treated joint.

### Statistical analysis

WOMAC and VAS scores differences with pre-treatment values were tested with nonparametric Wilcoxon tests.

### Results

Overall, results showed a significant improvement in OA symptoms in the treated population one month after Lipocell therapy, which was maintained until the end of the follow-up at 12 months. Knee functional recovery — measured with WOMAC Score — ameliorated from 61.5 points before the treatment to 79.5 one month af-

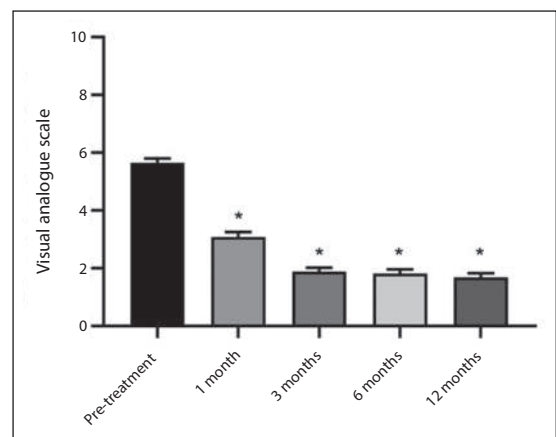


Figure 4.—Mean functional VAS Score (N.=92) before and after Lipocell treatment. Errors bars show SEM \*p vs. Pre-treatment <0.0001.

ter the injection. Functional recovery lasted at 3 (89.9), 6 (85.8), and 12 (84) months of follow-up (Figure 4). Pain — measured with VAS — was significantly reduced from 5.7 to 3.1 points at first month of follow-up, and relief was maintained at 3 (1.9), 6 (1.8), and 12 (1.7) months (Figure 5).

Out of 92 patients, 79 patients (85.9%) claimed a satisfactory outcome after the therapy reporting an excellent improvement both in pain relief and functional recovery.

MRI was performed on 10 patients after 6 months of follow-up: an evident reduction or even disappearance of peri-lesional subchondral edema was observed in 8 patients; 9 patients had no evidence of hemarthrosis, only 1 patient showed a mild effusion; 1 patient showed decrease of the chondral lesion (Figure 6).

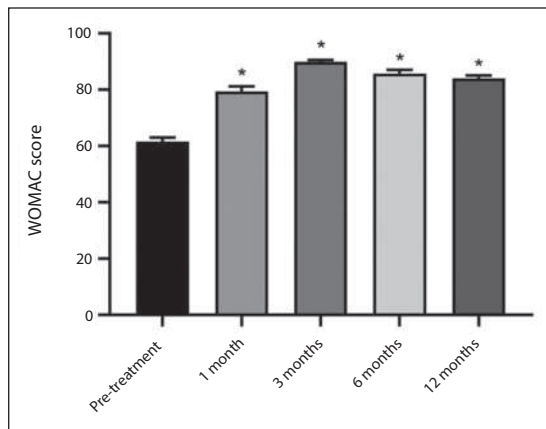


Figure 5.—Mean functional WOMAC Score (N=92) before and after Lipocell treatment. Errors bars show SEM \*p vs. Pretreatment <0.0001.

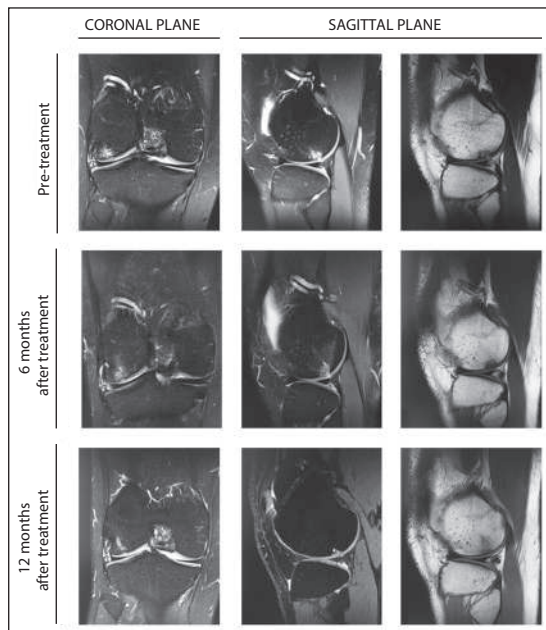


Figure 6.—Representative MRI scans of joint status progression after Lipocell infiltration. Right knee of 18 years old patient with MRI evidences of cartilage lesion in the lateral femoral condyle before the surgery, improved at 6 and 12 months. Left and central sequences are T1-weighted; right sequences are T2-weighted.

### Discussion

Regenerative medicine is a growing subject in daily orthopedic practice, and point-of-care systems are blooming because of their compliance with European and American cell therapy regulations. We tested the clinical outcome of 92 pa-

tients affected by stage II and II knee OA treated with intra-articular administration of purified adipose tissue with a centrifuge-independent point-of-care medical device. We found that the therapy is effective in ameliorating the pain and functional symptoms after one month from the injection; the beneficial results are maintained until one year. MRI images showed an improvement in the subchondral edema, which is one of the leading causes of knee pain.<sup>14</sup> The mechanical characteristics of fat tissue may provide a cushioning effect — in a viscosupplementation fashion — protecting cartilage surfaces from mechanical stress.

Moreover, adipose-derived MSCs can release anti-inflammatory cytokines to modulate the immune response towards regenerative pathways.<sup>8</sup> Improvements at mid and late follow-up may be due to changes in the articular environment. Exogenous MSCs can enhance the articular homeostasis through the release of several molecules in an exosome-dependent fashion, improving the quality of synovial fluid, lowering the inflammation, and nourishing the peri-articular structures.

Our results are confirmed by several studies, where patients were treated either with isolated MSCs (expanded or not)<sup>12, 15</sup> or with adipose tissue derivatives.<sup>10, 11, 16</sup> Because of regulatory restrictions on cell modifications, minimally-manipulated adipose tissue derivatives are becoming an optimal, cost-effective, and reproducible therapy.

### Limitations of the study

One limitation of these studies is the lack of standardization in pre- and post-treatment rehabilitation programs.<sup>17</sup> In our study, patients performed quadriceps strengthening and we suggested inductive magnetic field therapy. Further studies are required to assess if the use of physical treatments can boost the effects of regenerative medicine procedures.

### Conclusions

Because of regulatory restrictions on cell modifications, minimally-manipulated adipose tissue derivatives simple to be an optimal, cost-effective, and reproducible therapy for the treatment of early stages knee osteoarthritis. More studies

are necessary to explore all the mechanisms of action of this innovative and autologous therapy. Because of the positive clinical outcome at one year of follow-up, we will observe the results at two and even more years of follow-up to measure the duration of the efficacy of intra-articular injection of purified adipose tissue.

## References

- Dunlop DD, Manheim LM, Song J, Chang RW. Health care utilization among older adults with arthritis. *Arthritis Rheum* 2003;49:164–71.
- London NJ, Miller LE, Block JE. Clinical and economic consequences of the treatment gap in knee osteoarthritis management. *Med Hypotheses* 2011;76:887–92.
- Kon E, Filardo G, Drobnic M, Madry H, Jelic M, van Dijk N, *et al.* Non-surgical management of early knee osteoarthritis. *Knee Surg Sports Traumatol Arthrosc* 2012;20:436–49.
- Wernecke C, Braun HJ, Dragoo JL. The effect of intra-articular corticosteroids on articular cartilage: A systematic review. *Orthop J Sports Med* 2015;3:2325967115581163.
- Cooper C, Rannou F, Richette P, Bruyère O, Al-Daghri N, Altman RD, *et al.* Use of Intraarticular Hyaluronic Acid in the Management of Knee Osteoarthritis in Clinical Practice. *Arthritis Care Res (Hoboken)* 2017;69:1287–96.
- Dimarino AM, Caplan AI, Bonfield TL. Mesenchymal stem cells in tissue repair. *Front Immunol* 2013;4:201.
- Wu L, Cai X, Zhang S, Karperien M, Lin Y. Regeneration of articular cartilage by adipose tissue derived mesenchymal stem cells: perspectives from stem cell biology and molecular medicine. *J Cell Physiol* 2013;228:938–44.
- Murphy MB, Moncivais K, Caplan AI. Mesenchymal stem cells: environmentally responsive therapeutics for regenerative medicine. *Exp Mol Med* 2013;45:e54–16.
- Baer PC, Geiger H. Adipose-derived mesenchymal stromal/stem cells: tissue localization, characterization, and heterogeneity. *Stem Cells Int* 2012;2012:812693.
- Adriani E, Moio M, Di Paola B, Salustri W, Alfieri A, Parisi P, *et al.* Percutaneous fat transfer to treat knee osteoarthritis symptoms: preliminary results. *Joints* 2017;5:89–92.
- Roato I, Belisario DC, Compagno M, Lena A, Bistolfi A, Maccari L, *et al.* Concentrated adipose tissue infusion for the treatment of knee osteoarthritis: clinical and histological observations. *Int Orthop* 2019;43:15–23.
- Perdisa F, Gostyńska N, Roffi A, Filardo G, Marcacci M, Kon E. Adipose-Derived Mesenchymal Stem Cells for the Treatment of Articular Cartilage: A Systematic Review on Preclinical and Clinical Evidence. *Stem Cells Int* 2015;2015:597652.
- Ferracini R, Adriani E, Sabry O. A Novel Method to Optimize Autologous Adipose Tissue Recovery with Extracellular Matrix Preservation. *Processes (Basel)* 2020;8:88.
- Felson DT, Niu J, Guermazi A, Roemer F, Aliabadi P, Clancy M, *et al.* Correlation of the development of knee pain with enlarging bone marrow lesions on magnetic resonance imaging. *Arthritis Rheum* 2007;56:2986–92.
- Usuelli FG, D'Ambrosi R, Maccario C, Indino C, Manzi L, Maffulli N. Adipose-derived stem cells in orthopaedic pathologies. *Br Med Bull* 2017;124:31–54.
- Moshref SS, Kaki AM, Al-Hibshi AM, Jamal YS. Intra-articular injection of autologous fat micro-graft for the treatment of knee osteoarthritis: preliminary experience. *Life Sci J* 2014;11:55–60.
- McKay J, Frantzen K, Vercruyssen N, Hafsi K, Opitz T, Davis A, *et al.* Rehabilitation following regenerative medicine treatment for knee osteoarthritis-current concept review. *J Clin Orthop Trauma* 2019;10:59–66.

*Conflicts of interest.*—The authors certify that there is no conflict of interest with any financial organization regarding the material discussed in the manuscript.

*History.*—Manuscript accepted: February 18, 2020. - Manuscript received: February 12, 2020.